

Sergio Alexandre Gehrke
 Ulisses Tavares da Silva
 Neto
 Paulo Henrique Orlato
 Rossetti
 Sidney Eiji Watinaga
 Gabriela Giro
 Jamil Awad Shibli

Stability of implants placed in fresh sockets versus healed alveolar sites: Early findings

Authors' affiliations:

Sergio Alexandre Gehrke, Biotecnos Research Center, Santa Maria, Brazil
 Catholic University of Uruguay, Montevideo, Uruguay
 Sergio Alexandre Gehrke, Sidney Eiji Watinaga, Gabriela Giro, Jamil Awad Shibli, Department of Periodontology and Oral Implantology, Dental Research Division, University of Guarulhos, Guarulhos, Brazil
 Ulisses Tavares da Silva Neto, Postgraduate Program – Implantology, APCD, Jundiaí, Brazil
 Ulisses Tavares da Silva Neto, Leopoldo Mandic University, Campinas, Brazil
 Paulo Henrique Orlato Rossetti, Private Practice, Bauru, Sao Paulo, Brazil

Corresponding author:

Prof. Dr. Sergio Alexandre Gehrke
 Rua Dr. Bozano, 571
 PC: 97015-001 – Santa Maria (RS)
 Brazil
 Tel./Fax: +55 32227253
 e-mail: sergio.gehrke@hotmail.com

Key words: dental implant, fresh extraction sockets, implant stability, longitudinal studies, resonance frequency analysis

Abstract

Objectives: The present study measured implant stability quotient (ISQ) values at three different time points after surgical procedures to compare whether the stability values differed between implants placed in fresh extraction sockets versus healed alveolar sites.

Materials and methods: To measure implant stability, resonance frequency analysis (RFA) was performed in 77 patients (53 women, 24 men) with a total of 120 dental implants. These implants were divided into two groups: *Group 1* included 60 implants in healed alveolar sites (22 in the maxilla, 38 in the mandible), and *Group 2* included 60 implants in fresh sockets (41 in the maxilla, 19 in the mandible). Implant stability was measured immediately at implant placement (baseline), 90, and 150 days later. Statistical analysis was made using a multivariate regression linear model at implant level ($\alpha = 0.05$).

Results: Overall, the means and standard deviations of the ISQ values were 62.7 ± 7.14 (95% confidence interval [CI], 39–88) at baseline, 70.0 ± 6.22 (95% CI, 46–88) at 90 days, and 73.4 ± 5.84 (95% CI, 58–88) at 150 days. In *Group 1*, the ISQs ranged between 64.3 ± 6.20 and 75.0 ± 5.69 , while in *Group 2*, presented lower values that ranged between 61.2 ± 8.09 and 71.9 ± 5.99 ($P = 0.002$). Anatomic location and times periods were the only identified variables with an influence on ISQ values at implant level ($P < 0.0001$).

Conclusions: The stabilities of the implants placed in the fresh sockets and in healed sites exhibited similar evolutions in ISQ values and thus osseointegration; however, the implants in the healed alveolar sites exhibited superior values at all time points.

Immediate implants positioned in the course of tooth extraction exhibit a success ranging from 92.7% to 98.0% (Peñarrocha et al. 2004). However, in long-term observations, no significant differences in the success and aesthetic outcomes have been reported between immediate and delayed implants (Grunder et al. 1999; Mangano et al. 2012).

The surgical requirements for immediate implants include atraumatic tooth extraction, preservation of the extraction socket walls, and thorough alveolar curettage to eliminate any possible pathological material. Also, primary implant stability is also an essential requirement and is achieved through the use of implants that exceed the alveolar apex by 3–5 mm or by placing a dental implant with

a greater diameter than the alveolar socket (Becker & Becker 1996; Barone et al. 2006).

Implant stability is a prerequisite for the long-term clinical success of implant-supported restorations and depends on the quantity and quality of the local bone, the implant geometry, and the surgical technique used (sub-instrumentation vs. over-instrumentation) (Friberg et al. 1999; Dottore et al. 2014). The changes that occur during tissue healing, such as bone resorption and integration of the bone–implant interface, can determine the degree of the secondary implant stability. Obviously, the healing process will be affected by bone morphology, including its trabecular pattern, density, and the degree of maturation (Zix et al. 2008).

Date:
 Accepted 6 May 2015

To cite this article:

Gehrke SA, da Silva Neto UT, Rossetti PHO, Watinaga SE, Giro G, Shibli JA. Stability of implants placed in fresh sockets versus healed alveolar sites: early findings.
Clin. Oral Impl. Res. 00, 2015, 1–6
 doi: 10.1111/clr.12624

Resonance frequency analysis (RFA) offers a clinical, noninvasive measure of stability and presumed osseointegration of implants (Meredith et al. 1997a,b; Meredith 1998; Barewal et al. 2003) and is a useful tool to establish timing for implant loading (Uribe et al. 2005). Clinically, RFA values have been correlated with changes in implant stability during osseous healing, the failure of implants to integrate, and the supracrestal dimensions of the implant (Meredith 1998; Friberg et al. 1999).

Therefore, the objective of the present study was to measure implant stability quotient (ISQ) values at three different time points after surgical placement (immediately, 90, and 150 days later) to evaluate the influence of dental implant placement in fresh extraction sockets compared to healed sites.

Material and methods

Patient population

A total of 77 patients were included in this study. There were 53 women and 24 men, and the patients' ages ranged from 26 to 65 years. The study was approved by the Ethics and Research Committee of São Leopoldo Mandic University (Campinas, Brazil). All patients were informed regarding the nature of the study and their participation, and according to the Helsinki Declaration of 1994, every patient provided written consent.

The inclusion criteria were based on the patients' current stable medical conditions, their ability to withstand the stress of a dental implant surgery, and their requests for implants in their maxilla or mandible. All included patients agreed to participate in the implant stability study based on resonance frequency analysis for a period of 150 days. Additionally, cases where immediate loading was not indicated were also included. The patients were not included if they presented with systemic alterations such as diabetes, hypertension or osteoporosis, oral pathology in their soft or hard tissues, or harmful oral habits such as bruxism and smoking. The exclusion criteria based on the local implant site included the presence of uncontrolled or untreated periodontal disease, insufficient bone volume for implant insertion without augmentation procedures, and active infection in the area or an apical cyst.

Dental Implant surface topography

In this study, screw-shaped implants made of grade 4 titanium (Fig. 1 – Implacil De Bortoli, São Paulo, Brazil) were prepared by sand-



Fig. 1. Designs of the implants used in the study. Notably, the differences between the implant models were restricted to the cervical portion and the connection type (i.e., internal hexagon or Morse taper).

blasted acid-etched surface technology as previously described (Pita et al. 2014). The acid-etching process was controlled to create a homogeneous implant surface topography. The implants were blasted with 50–100 μm TiO_2 particles. After sandblasting, the dental implants were ultrasonically cleaned with an alkaline solution, washed in distilled water, and pickled with maleic acid ($\text{HO}_2\text{CCH}_2\text{CHOHCO}_2\text{H}$).

An optical laser profilometer (Mahr GmbH, Brauweg 38 Gottingen, Germany) was used to measure the implant surface microtopography. Parameters such as the mean and standard deviation of the absolute values of all profile points (Ra), the root mean square of the values of all points (Rq), and the average value of the absolute heights of the five highest peaks and the depths of the five deepest valleys (Rz) were of 0.87 ± 0.14 , 1.12 ± 0.18 , and 5.14 ± 0.69 μm , respectively.

Experimental design

The patients were divided into two groups as follows: Group 1 ($n = 34$ subjects) included 60 implants in the healed alveolar sites (25 in maxilla and 35 in mandible), and Group 2 ($n = 43$ subjects) included 60 immediately placed implants in the fresh extraction sockets (36 in the maxilla and 24 in the mandible). The inclusion criterion on the group was based on the clinical site condition (healed or fresh extraction sockets). The following clinical information was collected: patient age, gender, implant location, implant macro-geometry, implant length and diameter, and condition of the implantation site. The implant connection chosen was not randomized (internal hexagon or Morse taper).

Surgical procedure

Standard routine surgical procedures were applied. The patients were pre-medicated with amoxicillin (875 mg orally twice per day) for 5 days, and an initial dose (2 g) was administered 2 h before surgery. All surgical

procedures were performed under local anesthesia with 2% articaine (DFL Ltda, Rio de Janeiro, Brazil) in an outpatient setting by the same surgeon who was familiar with the dental implant system. Next, a full thickness mucoperiosteal flap was elevated at the sites in Group 1, and in Group 2, following tooth extraction, the osteotomy was realized. The osteotomies were produced using the conventional drilling method (according to the manufacturer's instructions). A total of 120 conical implants were applied and included internal hexagon ($n = 69$) and Morse taper ($n = 51$) connections in diameters of 3.5 mm ($n = 36$) or 4 mm ($n = 84$) and lengths that ranged from 8 to 13 mm. The implants were selected based on the prior evaluation of each case. The selections of the connection types were based on differences in the characteristics of the cervical areas of these two models as shown in Fig. 1.

For drilling, a Kavo Concept motor (KaVo Dental GmbH, Biberach, Germany) and a counter angle with a 27:1 reduction were used under external irrigation with 0.9% saline solution. All implants were installed using surgical guides, and the wounds were sutured. Cetoprofeno (200 mg/day) and paracetamol (750 mg, three times per day) were administered for pain relief for 3 days after the surgeries. All implants were submerged for 90 days with a healing abutment until the initiation of rehabilitation after 150 days. Between 90 and 150 days, restorative procedures were performed.

After dental implant insertion, evaluation of the resonance frequency evaluation was performed using the Ostell™ Mentor (Integration Diagnostics AB, Göteborg, Sweden) with magnetic RFA measurements. A Smartpeg™ (Integration Diagnostics AB) was placed into each implant and tightened to approximately 5 Ncm. The transducer probe was aimed at the small magnet at the top of the Smartpeg at a distance of 2 or 3 mm and held stable during the pulsing until the instrument

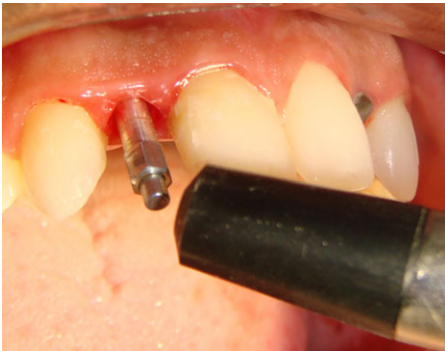


Fig. 2. The measurement of ISQ using the Osstell Mentor™.

beeped and displayed the ISQ value. The ISQ values were measured during the surgical procedure (T1 – baseline), at 90 days (T2), and at 150 days (T3) after surgeries (Fig. 2). The measurements were taken twice in the bucco-lingual direction and the mesio-distal direction (Sim & Lang 2010). The mean of the two measurements in each direction was regarded as the representative ISQ for that direction and considered for statistical analysis. The higher bucco-lingual and mesio-distal ISQ values were used to generate a mean value, and all values were recorded. Additionally, each implant was evaluated at all visits for mobility, pain, and signs of infection.

Statistical analysis

The statistical analysis was performed using a multivariate linear regression model (McCulloch & Searle 2000) considering: implant diameter, length, connection, surgical site condition, anatomic location, and time periods. The ISQ value was the dependent variable. The level of significance was set at $\alpha = 0.05$.

Results

Seventy-seven patients (53 women and 24 men; ages from 26 to 65 years) received dental implants. Detailed distributions for the groups regarding implant diameter, length, connection, and ISQ values over investigated time periods by arch type are depicted in Table 1. The detailed distributions for the Groups are depicted in Figs 3 and 4. All implants survived and were osseointegrated. Dropouts were not observed during the evaluation period.

Overall, the mean and standard deviation of ISQ values were 62.7 ± 7.14 (95% CI: [39–88]) at T1, 70.0 ± 6.22 (95% CI, [46–88]) at T2, and 73.4 ± 5.84 (95% CI: [58–88]) at T3. In the maxillary arch, the overall ISQ values for G1 and G2 were 70.23 and 67.07, respectively. In

Table 1. Demographic data

	Surgical site condition					
	Extraction sockets (G2)			Healed sockets (G1)		
Number of patients (total)	43			34		
Number of implants (total)	60			60		
Maxilla (per implant)						
<i>Diameter</i>						
3.5 mm	13			18		
4.0 mm	23			17		
<i>Length</i>						
8 mm	0			0		
10 mm	3			7		
11 mm	14			15		
13 mm	19			13		
<i>Connection type</i>						
IH	15			16		
CM	21			19		
Mandible (per implant)						
<i>Diameter</i>						
3.5 mm	1			4		
4.0 mm	23			21		
<i>Length</i>						
8 mm	1			6		
10 mm	17			16		
11 mm	5			3		
13 mm	1			0		
<i>Connection type</i>						
IH	17			21		
CM	7			4		
Mandible (ISQ values)						
	T1	T2	T3	T1	T2	T3
<i>Mean</i>	64.41	73.11	75.52	67.51	74.68	76.22
<i>SD</i>	5.15	5.95	5.04	5.15	6.54	5.80
<i>No. of implants ISQ \geq 65</i>	17	34	36	23	35	35
<i>No. of implants ISQ < 65</i>	19	2	0	12	0	0
Maxilla (ISQ values)						
	T1	T2	T3	T1	T2	T3
<i>Mean</i>	63.83	70.58	74.04	63.68	69.96	73.72
<i>SD</i>	7.59	7.76	6.40	7.23	8.35	5.51
<i>No. of implants ISQ \geq 65</i>	10	20	22	13	22	23
<i>No. of implants ISQ < 65</i>	14	4	2	12	3	2

IH, internal hex; CM, cone Morse; ISQ, implant stability quotient; T1, baseline; T2, at 90 days; T3, at 150 days.

the mandibular arch, the ISQ values for G1 and G2 were 70.57 and 66.74, respectively.

In Group 1, the mean and standard deviation ISQ values at T1, T2, and T3 were 64.3 ± 6.20 , 72.1 ± 5.58 , and 75.0 ± 5.69 , respectively. In Group 2, the corresponding values were 61.2 ± 8.09 , 67.9 ± 6.86 , and 71.9 ± 5.99 .

The multivariate regression analysis identified that only two factors (anatomic location, time period) had an influence on ISQ values ($R^2 = 0.3249$; R^2 adjusted = 0.3211; multiple correlation coefficient = 0.57; both factors with $P < 0.0001$). Site location (extraction x healed) did not demonstrate influence on ISQ values as shown in Table 1.

Discussion

This clinical study describes a comparison of the resonance frequency analysis of implants

placed into fresh sockets and healed sites at three different time periods. No implants were lost throughout the study short-time period, and the survival rate of dental implants in the present study was 100%. Initial implant stability plays a pivotal role in achieving osseointegration. A significant relationship was found between the bone type and ISQ values (Balleri et al. 2002; Barewal et al. 2003; Bischof et al. 2004; Nedir et al. 2004; Oates et al. 2007; Dottore et al. 2014). The quantity and location of cortical and trabecular bone surrounding the implants are important factors for stability because these factors contribute to bone-implant contact (Meredith 1998).

Dental implants placed in fresh sockets presented several advantages, such as reductions in surgical trauma and the treatment time. It has also been reported that the immediate placement of implants can

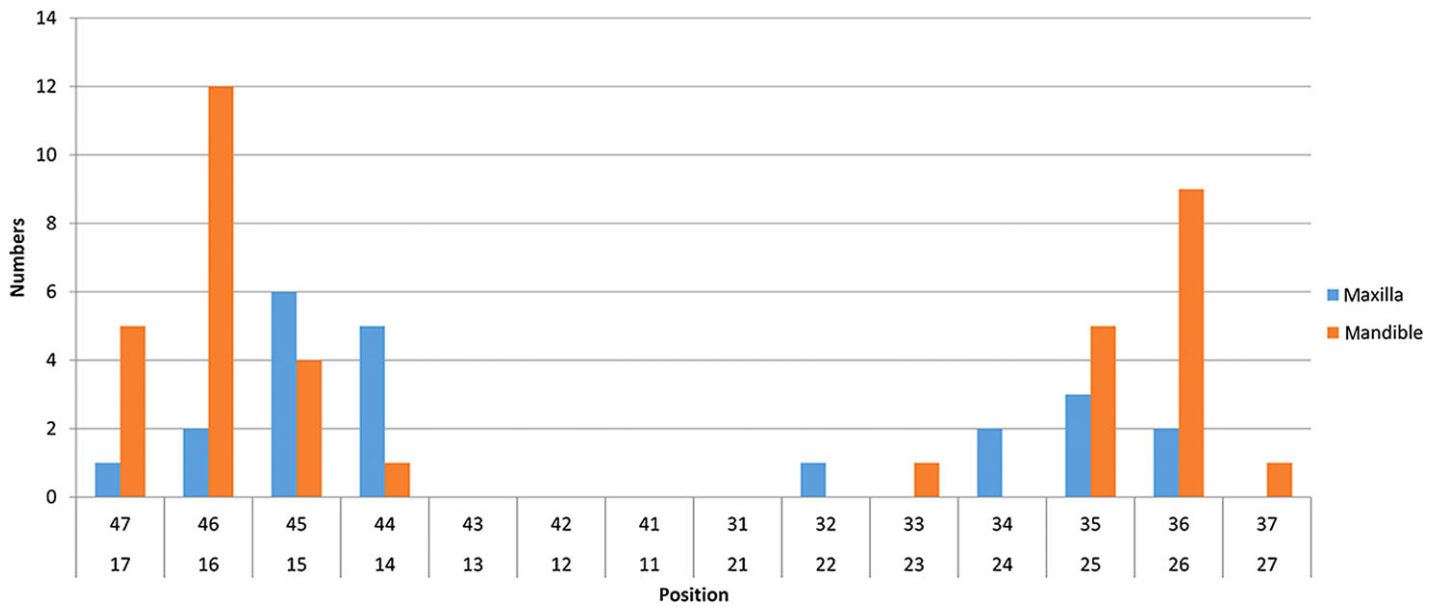


Fig. 3. Bar graph showing the detail distributions of the implants in Group 1 (healed sites).

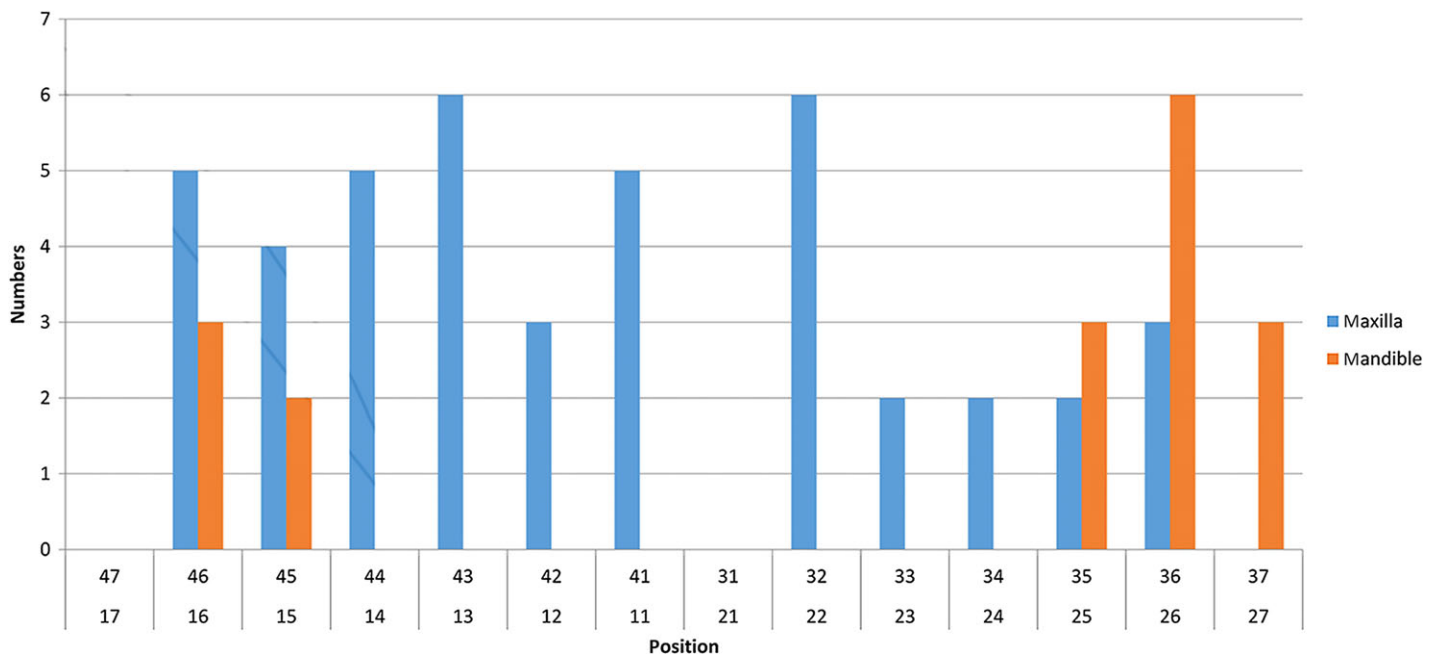


Fig. 4. Bar graph showing the detailed distribution of the implants in Group 2 (fresh extraction sockets).

prevent bone resorption and might result in better remodeling of the socket. For these favorable outcomes, the placement of the implant at the palatal aspect of the socket seems to be important for the prevention of gingival recession (Kahnberg 2009). Also, it has been suggested that immediate and immediate-delayed implants might be associated with greater risks of implant failure and complications compared to delayed implants; however, the esthetic outcomes of implants placed immediately after tooth extraction

might be superior (Mangano et al. 2013). There is not enough reliable evidence to support or refute the need for augmentation procedures for immediate implants placed in fresh extraction sockets or to determine whether any of the augmentation techniques are superior to the others (Esposito et al. 2010).

The clinical methods that are commonly used to assess implant stability and osseointegration include percussion, mobility tests, and clinical radiographs. All of these meth-

ods are limited by their lack of standardization, poor sensitivity, and susceptibility to operator variables (Meredith et al. 1997a,b; Fischer et al. 2009). In the last decade, a modern and noninvasive diagnostic technique called resonance frequency analysis (RFA) was used for the evaluation and measurement of the stability of implants within bone at different clinical stages (Meredith et al. 1997a,b; da Silva Neto et al. 2013). The reasons for the use of this technique are that it is rapid, straightforward, easy to

accomplish as part of a routine clinical procedure, and there is no risk of patient discomfort.

During the bone-healing period, the implants' ISQ value varied with time. At the surgical phase, the average ISQ for all implants was 62.7 ± 7.14 , which indicates good primary stability and is similar to results obtained in different studies using different type of implants that have reported averages ranging from 60.3 to 62.6 (Friberg et al. 1999; Zix et al. 2008). When the stability of the implants was evaluated after tooth extraction, the mean value of the stability measures taken immediately after implant placement was 62.0 ± 9.8 , and the secondary stability after 1 year was 64.0 ± 9.8 (Becker et al. 2005). In our study, the overall mean ISQ values of the implants that were placed in fresh sockets were 61.2 ± 8.09 at time 1 and increased to 67.9 ± 6.86 at 90 days and to 71.9 ± 5.99 at 150 days post-insertion.

The majority of the implants in the maxilla had ISQs < 60 , and those in the mandible had ISQs > 60 (Nedir et al. 2004). Other studies have demonstrated that, following surgery, the average ISQ values are higher in the mandible (59.8 ± 6.7) than in the maxilla (55.0 ± 6.8) when cylindrical implants are used (Bischof et al. 2004). In the present study, the average values were 64.3 for Group 1 and 61.2 for Group 2. In all cases, the values of the present study (which used conical implants) were higher than those reported in the aforementioned study (which used cylindrical implants); this difference might be related to the different types of implant used. However, we observed that the average values significantly increased after 90 and 150 days.

Bone density also influences initial implant stability during insertion (Molly 2006; Turkyilmaz et al. 2009). The reported average bone densities of the implant sites in a previous study (Turkyilmaz et al. 2007) were 856.8 Hounsfield units (HU) for the mandible and 594.2 HU for the maxilla. However, earlier study (Devlin et al. 1998) had reported a mean bone mineral density of the mandible of 1.11 g per square centimeter pressure units (g/cm^2), which is much larger than that in the anterior maxilla (mean = $0.55 \text{ g}/\text{cm}^2$) or the posterior maxilla (mean = $0.31 \text{ g}/\text{cm}^2$). This result is consistent with the results of the present study in which the mandible

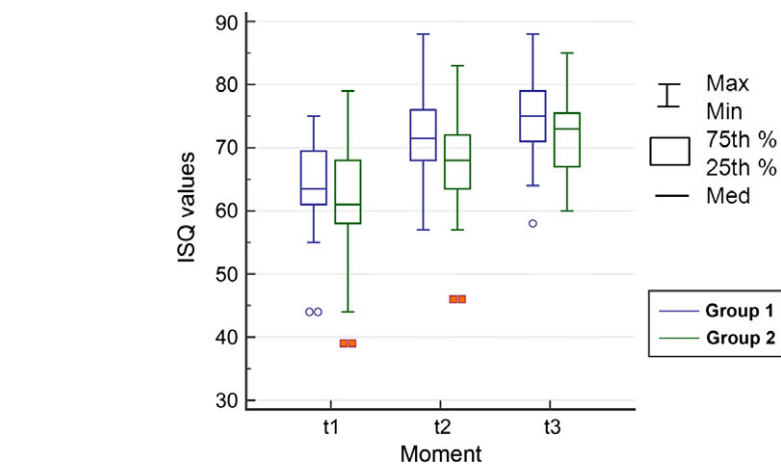


Fig. 5. Box plots showing the comparisons of the values between groups at the different time points. Outliers (blue circles and orange squares).

exhibited significantly higher ISQ values at all time points compared to the maxilla. Despite this difference, when we examined the Fig. 5 of the evolution of the ISQ values across the different time points, the behaviors of the two areas (i.e., the maxilla and mandible) were very similar, which suggests that the differences in stability values were due to the differences in bone density and not differences in the process and/or time for osseointegration.

Bone quality and implant stability are lower in the posterior area; thus, the posterior implant success rate is lower than the anterior rate. In the anterior area, the thick cortical bone and dense trabecular bone increase the primary stability (Lazzara et al. 1996). According to Seong et al. (2009), there is no consensus in the literature regarding how the physical properties of bone vary between the maxillary and mandibular regions or which physical properties affect the initial implant stability. A clinical study suggested that the use of thinner drills for implant placement in the maxillary posterior region where the bone quality is poor might improve the primary implant stability and help clinicians to obtain higher implant survival rates (Turkyilmaz et al. 2008). However, in our study, based on the data from the immediate implants (in both the maxilla and mandible), the majority of the implants were installed in the maxilla (71.6%), similar stabilities were observed in the anterior and posterior maxilla, and there were no differences independent of time.

Some authors have suggested that the use of longer and wider implants increases primary stability due to the increased bone-implant contact surface area (Balleri et al. 2002; Calandriello et al. 2003; Turkyilmaz et al. 2007). In the present study, only the diameter (3.5 mm vs. 4.0 mm) and the implant design and not the length of the implant were used as evaluation factors, and the results revealed significantly larger ISQ values with greater implant diameter ($P < 0.05$). These results are not consistent with those that have been found in other studies that have reported no statistically significant differences in ISQ due to length or diameter ISQ (Balleri et al. 2002; Ostman et al. 2006). Regarding the design of the implant, IH implants with cervical microthreads exhibited significantly higher stabilities at each of the three time points ($P < 0.05$). These results are consistent with the mean ISQ value of 62.4 for all of the measurements taken on the day of surgery that was reported in another study that used cylindrical implants with cervical microthreads.

Conclusions

The stabilities of the implants placed into fresh extraction sockets or at healed alveolar sites exhibited similar ISQ value evolutions across the three investigated time points.

Conflict of interests

The authors have no conflict of interests to declare.

References

- Balleri, P., Cozzolino, A., Ghelli, L., Momichioli, G. & Varriale, A. (2002) Stability measurements of osseointegrated implants using Osstell in partially edentulous jaws after one year of loading: a pilot study. *Clinical Implant Dentistry and Related Research* **4**: 128–132.
- Barewal, R.M., Oates, T.W., Meredith, N. & Cochran, D.L. (2003) Resonance frequency measurement of implant stability in vivo on implants with a sandblasted and acid-etched surface. *International Journal of Oral & Maxillofacial Implants* **18**: 641–651.
- Barone, A., Rispoli, L., Voza, I., Quaranta, A. & Covani, U. (2006) Immediate restoration of single implants placed immediately after tooth extraction. *Journal of Periodontology* **77**: 1914–1920.
- Becker, W. & Becker, B.E. (1996) Flap designs for minimization of recession adjacent to maxillary anterior implant sites. A clinical study. *International Journal of Oral & Maxillofacial Implants* **11**: 46–54.
- Becker, W., Sennerby, L., Bedrossian, E., Becker, B.E. & Lucchini, J.P. (2005) Implant stability measurements for implants placed at the time of extraction: a cohort, prospective clinical trial. *Journal of Periodontology* **76**: 391–397.
- Bischof, M., Nedir, R., Szmukler-Moncler, S., Bernard, J.P. & Samson, J. (2004) Implant stability measurement of delayed and immediately loaded implants during healing. *Clinical Oral Implants Research* **15**: 529–539.
- Calandriello, R., Tomatis, M., Vallone, R., Rangert, B. & Gottlow, J. (2003) Immediate occlusal loading of single lower molars using Branemark System Wide-Platform TiUnite implants: an interim report of a prospective open-ended clinical multicenter study. *Clinical Implant Dentistry and Related Research* **5**(Suppl 1): 74–80.
- Devlin, H., Horner, K. & Ledgerton, D. (1998) A comparison of maxillary and mandibular bone mineral densities. *Journal of Prosthetic Dentistry* **79**: 323–327.
- Dottore, A.M., Kawakami, P.Y., Bechara, K., Rodrigues, J.A., Cassoni, A., Figueiredo, L.C., Piattelli, A. & Shibli, J.A. (2014) Stability of implants placed in augmented posterior mandible after alveolar osteotomy using resorbable nonceramic hydroxyapatite or intraoral autogenous bone: 12-month follow-up. *Clinical Implant Dentistry and Related Research* **16**: 330–336.
- Espósito, M., Grusovin, M.G., Polyzos, I.P., Felice, P. & Worthinton, H.V. (2010) Timing of implant placement after tooth extraction: immediate, immediate-delayed or delayed implants? A Cochrane systematic review. *European Journal of Oral Implantology* **3**: 189–205.
- Fischer, K., Bäckström, M. & Sennerby, L. (2009) Immediate and early loading of oxidized tapered implants in the partially edentulous maxilla: a 1-year prospective clinical, radiographic, and resonance frequency analysis study. *Clinical Implant Dentistry and Related Research* **11**: 69–80.
- Friberg, B., Sennerby, L., Linden, B., Gröndahl, K. & Lekholm, U. (1999) Stability measurements of one-stage Branemark implants during healing in mandibles. A clinical resonance frequency analysis study. *International Journal of Oral and Maxillofacial Surgery* **28**: 266–272.
- Grunder, U., Polizzi, G., Goené, R., Hatano, N., Henry, P., Jackson, W.J., Kawamura, K., Köhler, S., Renouard, F., Rosenberg, R., Triplett, G., Werbit, M. & Lithner, B. (1999) A 3 year prospective multicenter follow-up report on the immediate and delayed immediate placement of implants. *International Journal of Oral & Maxillofacial Implants* **14**: 210–216.
- Kahnberg, K.E. (2009) Immediate implant placement in fresh extraction sockets: a clinical report. *International Journal of Oral & Maxillofacial Implants* **24**: 282–288.
- Lazzara, R., Siddiqui, A.A., Binon, P., Feldman, S.A., Weiner, R., Phillips, R. & Gonshor, A. (1996) Retrospective multicenter analysis of 3i endosseous dental implants placed over a five-year period. *Clinical Oral Implants Research* **7**: 73–83.
- Mangano, F., Mangano, C., Ricci, M., Sammons, R.L., Shibli, J.A. & Piattelli, A. (2012) Single-tooth Morse taper connection implants placed in fresh extraction sockets of the anterior maxilla: an aesthetic evaluation. *Clinical Oral Implants Research* **23**: 1302–1307.
- Mangano, F.G., Mangano, C., Ricci, M., Sammons, R.L., Shibli, J.A. & Piattelli, A. (2013) Esthetic evaluation of single-tooth Morse taper connection implants placed in fresh extraction sockets or healed sites. *Journal of Oral Implantology* **39**: 172–181.
- McCulloch, C.E. & Searle, S.R. (2000) Generalized, Linear, and Mixed Models. New York: John Wiley and Sons.
- Meredith, N. (1998) Assessment of implant stability as a prognostic determinant. *International Journal of Prosthodontics* **11**: 491–501.
- Meredith, N., Book, K., Friberg, B., Jemt, T. & Sennerby, L. (1997a) Resonance frequency measurements of implant stability in vivo. A cross-sectional and longitudinal study of resonance frequency measurements on implants in the edentulous and partially dentate maxilla. *Clinical Oral Implants Research* **8**: 226–233.
- Meredith, N., Shagaldi, F., Alleyne, D., Sennerby, L. & Cawley, P. (1997b) The application of resonance frequency measurements to study the stability of titanium implants during healing in the rabbit tibia. *Clinical Oral Implants Research* **8**: 234–243.
- Molly, L. (2006) Bone density and primary stability in implant therapy. *Clinical Oral Implants Research* **17**(Suppl 2): 124–135.
- Nedir, R., Bischof, M., Szmukler-Moncler, S., Bernard, J.P. & Samson, J. (2004) Predicting osseointegration by means of implant primary stability: a resonance frequency analysis with delayed and immediately loaded ITI SLA implants. *Clinical Oral Implants Research* **15**: 520–528.
- Oates, T.W., Valderrama, P., Bischof, M., Nedir, R., Jones, A., Simpson, J., Toutenburg, H. & Cochran, D.L. (2007) Enhanced implant stability with a chemically modified SLA surface: a randomized pilot study. *International Journal of Oral & Maxillofacial Implants* **22**: 755–760.
- Ostman, P.O., Hellman, M., Wendelhag, I. & Sennerby, L. (2006) Resonance frequency analysis measurements of implants at placement surgery. *International Journal of Prosthodontics* **19**: 77–83.
- Peñarocha, M., Uribe, R. & Balaguer, J. (2004) Immediate implants after extraction. A review of the current situation. *Medicina Oral* **9**: 234–242.
- Pita, P.P., Rodrigues, J.A., Ota-Tsuzuki, C., Miato, T., Giro, G., Zenobio, E.G., Gonçalves, C., Figueiredo, L.C., Cassoni, A., Gehrke, S.A. & Shibli, J.A. (2014) Oral streptococci biofilm formation on different implant surface topographies. *BioMed Research International* **2014**: 850120. doi: 10.1155/2014/850120.
- Seong, W.J., Kim, U.K., Swift, J.Q., Hodges, J.S. & Ko, C.C. (2009) Correlations between physical properties of jawbone and dental implant initial stability. *Journal of Prosthetic Dentistry* **101**: 306–318.
- da Silva Neto, U.T., Joly, J.C. & Gehrke, S.A. (2013) Clinical analysis of the stability of dental implants after preparation of the site by conventional drilling or piezosurgery. *British Journal of Oral and Maxillofacial Surgery* **19**: pii: S0266-4356(13)00471-3. doi: 10.1016/j.bjoms.2013.10.008.
- Sim, C.P. & Lang, N.P. (2010) Factors influencing resonance frequency analysis assessed by Osstell Mentor during implant tissue integration: I. Instrument positioning, bone structure, implant length. *Clinical Oral Implants Research* **21**: 598–604.
- Turkylmaz, I., Aksoy, U. & McGlumphy, E.A. (2008) Two alternative surgical techniques for enhancing primary implant stability in the posterior maxilla: a clinical study including bone density, insertion torque, and resonance frequency analysis data. *Clinical Implant Dentistry and Related Research* **10**: 231–237.
- Turkylmaz, I., Sennerby, L., McGlumphy, E.A. & Tözüm, T.F. (2009) Biomechanical aspects of primary implant stability: a human cadaver study. *Clinical Implant Dentistry and Related Research* **11**: 113–119.
- Turkylmaz, I., Tözüm, T.F. & Tumer, C. (2007) Bone density assessments of oral implant sites using computerized tomography. *Journal of Oral Rehabilitation* **34**: 267–272.
- Uribe, R., Penarrocha, M., Balaguer, J. & Fulgueiras, N. (2005) Immediate loading in oral implants. Present situation. *Oral Surgery, Oral Medicine, Oral Pathology, Oral Radiology, and Endodontology* **10**(Suppl 2): E143–E153.
- Zix, J., Hug, S., Kessler-Liechti, G. & Mericske-Stern, R. (2008) Measurement of dental implant stability by resonance frequency analysis and damping capacity assessment: comparison of both techniques in a clinical trial. *International Journal of Oral & Maxillofacial Implants* **23**: 525–530.